

Aligners Can for Your Cants

Effective mechanics with aligners to manage occlusal cants and correct smile lines

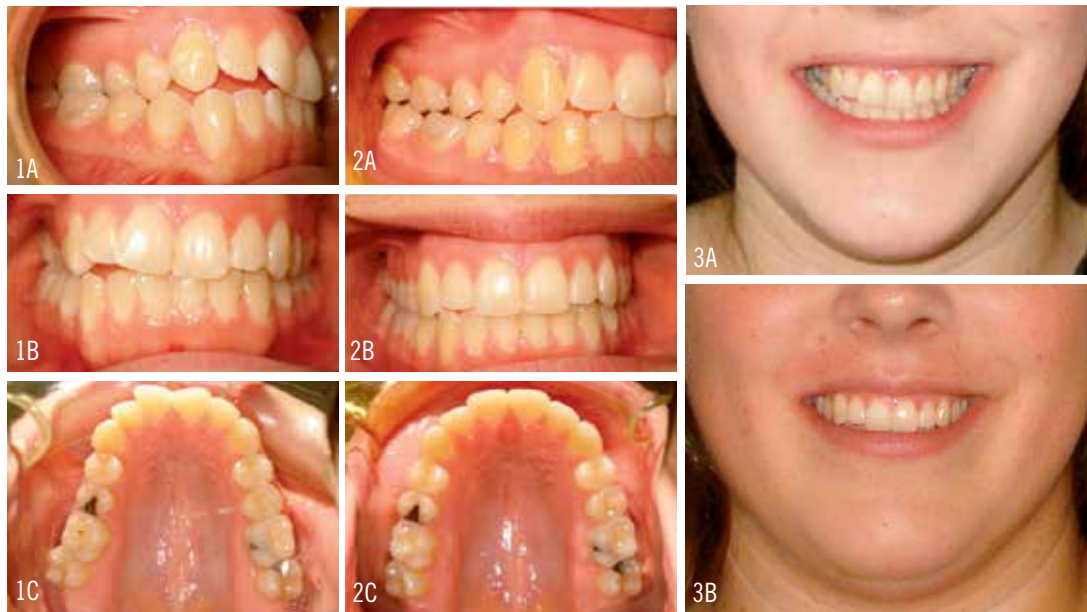
BY JONATHAN NICOZISIS, DMD, MS

If you think aligners can't correct your cants, then think again because they can! Occlusion is one thing, but being able to confidently address other cosmetic components of the smile with aligners only is a wonderful service to be able to offer your patients. This article provides a detailed review of Invisalign Clincheck design and mechanics to address reverse smile lines and occlusal cants using aligners only. The cases presented used aligners only without the use of any elastics, auxiliaries, or TADs.

Invisalign aligners have become my appliance system of choice for these cases because of the control advantage you have compared to fixed appliances, especially in the vertical dimension. The advantage is that there is none of the unwanted movement of anchor teeth when extruding down targeted teeth vertically that we often experience with fixed appliances. With fixed appliances, we end up needing elastics to compensate and augment our forces or to fix unwanted side effects after they have occurred. I simply do not have that issue with aligners, making for easier and more efficient treatment. In such cases, Invisalign has allowed me to work smarter and easier with greater clinical efficiency.

Extrusion Protocol

To address occlusal cants with aligners, the clinician must employ proper mechanics for extrusion to be able to use aligners only and without auxiliaries. In my opinion, effective extrusion is not the optimized extrusion attachment alone. Rather, it involves the optimized extrusion attachment



Case 1. Figures 1A-1C and 3A show initial crossbite. Figures 2A-2C and 3B show correction following 18 months of treatment with two refinements and no IPR.

for anterior teeth or horizontal rectangular beveled toward the gingival attachment for posterior teeth, plus a properly designed tooth movement protocol.

Given the fundamental understanding that our appliance system of choice is a plastic aligner that only pushes teeth and cannot pull teeth down along the long axis of the tooth to effect extrusion, the Clincheck must be designed to move the teeth out labially to create space interproximally and then move the teeth vertically toward the occlusal plane with simultaneous lingual retraction. This way, you get two vectors of force on the tooth simultaneously: one is extruding while the other is retracting. The net result is a pushing vector of force that is as perpendicular as possible against the broad surface of the horizontal rectangular attached that is beveled toward the gingival.

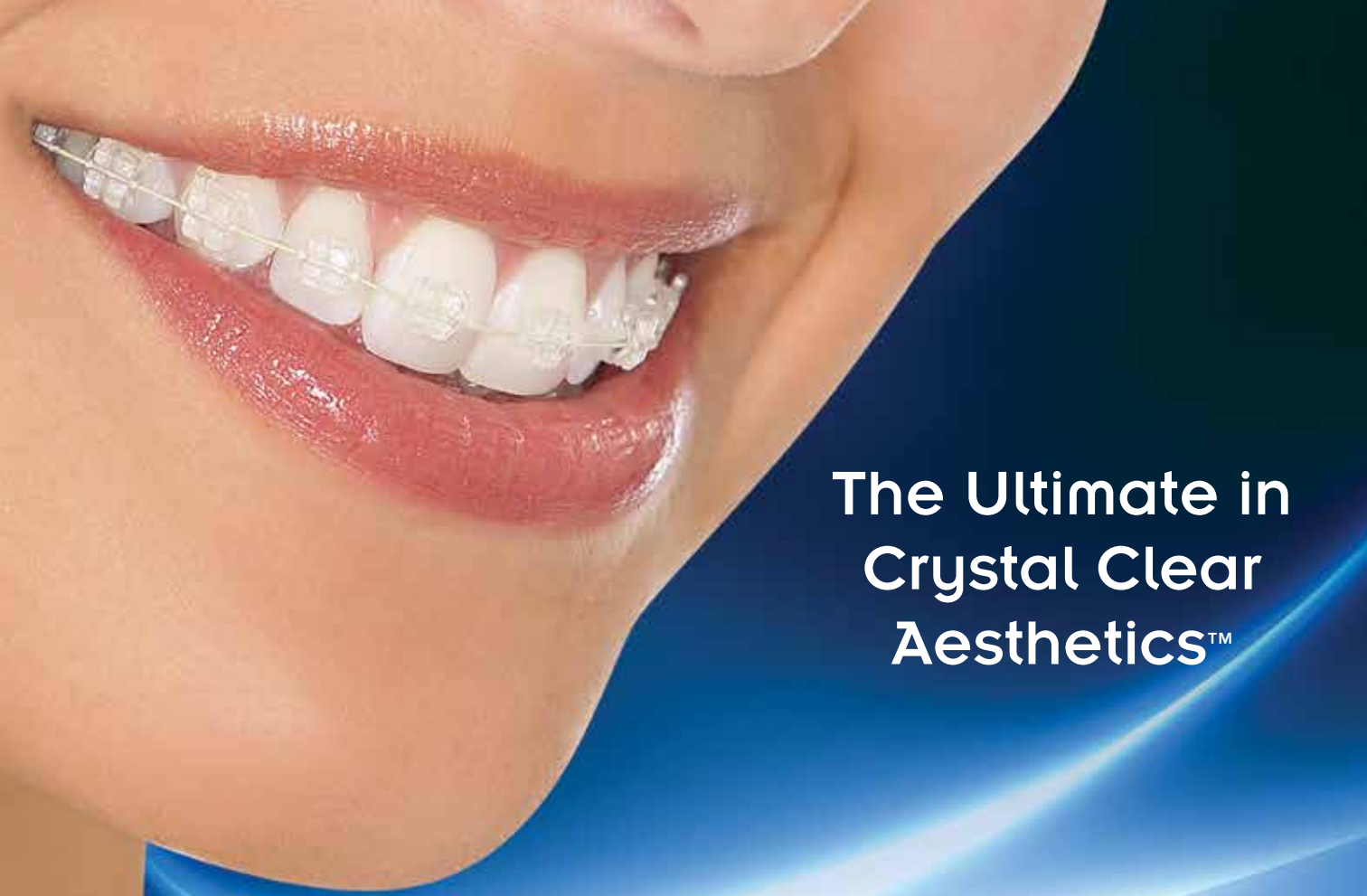Benchmark engineering testing from Align Technology Inc released in 2009 showed that this configuration is most effective in creating a repeatable force system to effect extrusion during the normal insertion and removal of aligners throughout the standard 2-week period. It is ideal to ask for all of the extrusion to be completed prior to complete space closure. This will ensure that there are no collisions when performing the movement and the last bit of movement is tightening

contacts with a virtual power chain. Thus, the amount of interproximal spacing that needs to be created is really a function of the amount of extrusion that is necessary.

To reiterate, effective extrusion is designed to bring teeth out labially creating space interproximally, where upper teeth, extrude them down toward the occlusal plane with simultaneous lingual retraction and where lower teeth, extrude them up occlusally with simultaneous lingual retraction.

JONATHAN NICOZISIS, DMD, MS, has been practicing since 1999. He completed his dental education at the University of Pennsylvania before attending Temple University for his orthodontic residency. He is a member of the Angle Society and Invisalign® National Speaker's Bureau and Clinical Research Network. He is also the founding orthodontist and former scientific advisory board member of BAS Medical (now Corthera). Nicozisis is also on the Scientific Advisory Board of PROPEL Orthodontics.





The Ultimate in Crystal Clear Aesthetics™

PURE®

Sapphire Bracket System



For Unparalleled Aesthetics, Comfort, and Strength the Choice is Crystal Clear

- Made from pure monocrystalline sapphire to ensure the highest transparency available for outstanding aesthetics
- Contoured tie-wings and ultra-smooth hooks for added patient comfort
- Nearly invisible against any tooth shade
- Brackets remain crystal clear without staining
- Diamond and heat polished for superior sliding mechanics
- Small bracket size and low profile design provide a desirable bracket for both clinicians and patients
- Ample tie-wing area for easy bracket ligation
- Bonding base is coated with zirconia spheres for secure retention and predictable debonding

Discover all of the benefits at www.orthotechnology.com/PURE

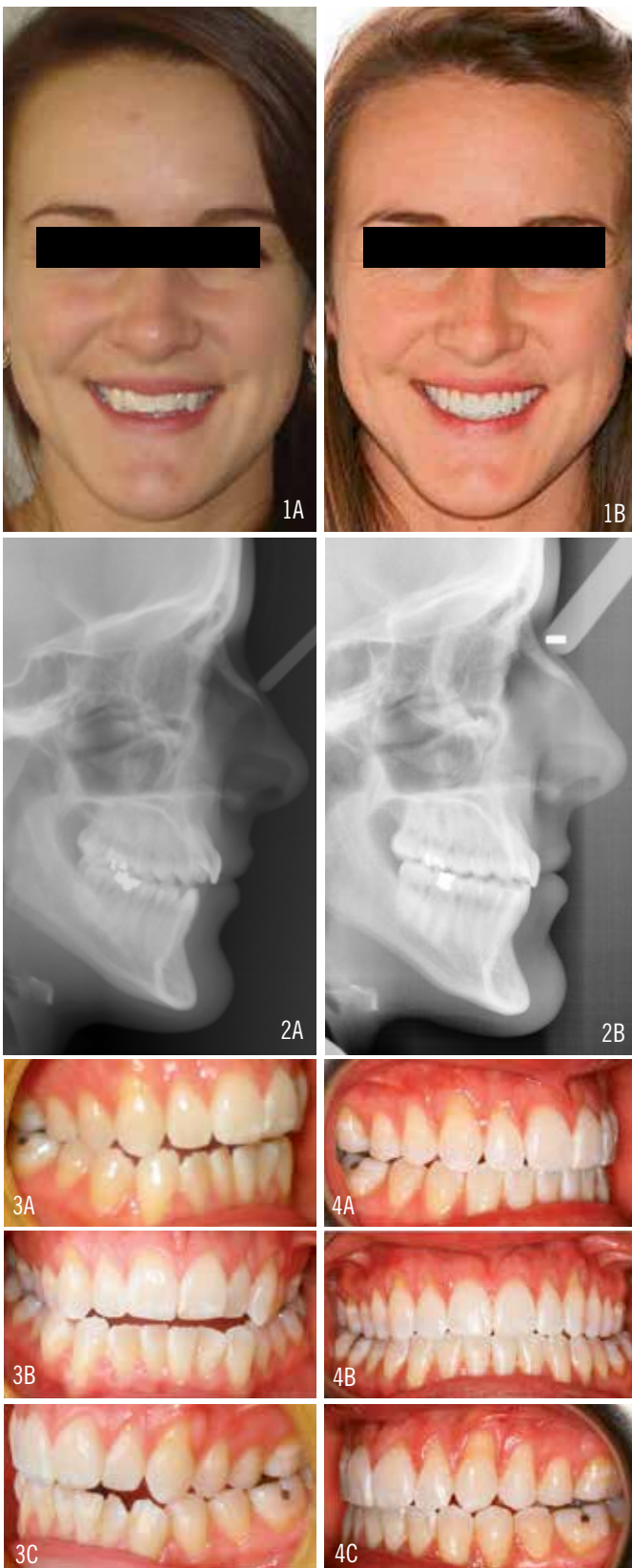
Call About Our 2 Free Trial Cases Today*
800-999-3161 | 813-991-5896



*Get 2 free patient cases (40 brackets) when you purchase 5 cases (100 brackets). Try PURE Brackets for the first time and if you are not completely satisfied then return the remaining cases and keep the two trial cases at no cost. Offer expires 10-31-2013. © 2013 Ortho Technology, Inc. PURE is a registered trademark of Ortho Technology, Inc.



Treatment Plan



Case 2. Figures 1A, 2A, and 3A-3C show anterior open bite. Figures 1B, 2B, and 4A-4C show the results of treatment using posterior intrusion of U/L 4, 5, 6, and 7's 2 mm each to finish with a posterior open bite in the Clincheck without a surgical jump and extrusion protocol mechanics of the upper 3-3 to improve the smile line. IPR was one on lower 3-3. Total treatment time was 21 months.

Case 1

Total treatment time 18 months with two refinements and no IPR. Crossbite correction achieved by moving upper right buccal segment out in a bodily fashion and lower right segment lingually in a bodily fashion. Lateral open bite and occlusal cant corrected using extrusion protocol mechanics on numbers 4, 5, 6, 7, 8, 27, 28, and 29, combined with intrusion of the right upper and lateral (U/L) first and second molars. This active intrusion of the U/L right first and second molars in the Clincheck mimic fixed appliances, and the intrusive forces imparted on the molars if the teeth in the buccal segments were stepped down and up toward the occlusal plane to close down the lateral open bite (See figures on page 16).

The keen clinician simply recognizes the forces created with fixed appliances and translates that to the Clincheck.

Case 2

Total treatment time 21 months. Mechanics used to close the anterior open bite were posterior intrusion of U/L 4, 5, 6, and 7's 2 mm each to finish with a posterior open bite in the Clincheck without a surgical jump and extrusion protocol mechanics of the upper 3-3 to improve the smile line. Autorotation of the mandible maintains occlusal contact of the posterior teeth so the patient never experiences a posterior open bite clinically. IPR was done on lower 3-3 prior to the first impression due to the small upper laterals and Class 3 skeletal pattern (See figures at left).

These mechanics mimic that employed by the MEAW (Multi-Loop Edgewise Arch Wire) Appliance where there are boot-loops bent between the brackets from the cuspids to the second molars with progressive tip-back bends to help intrude and upright the posterior teeth along the occlusal plane. The MEAW appliance necessitates that patients

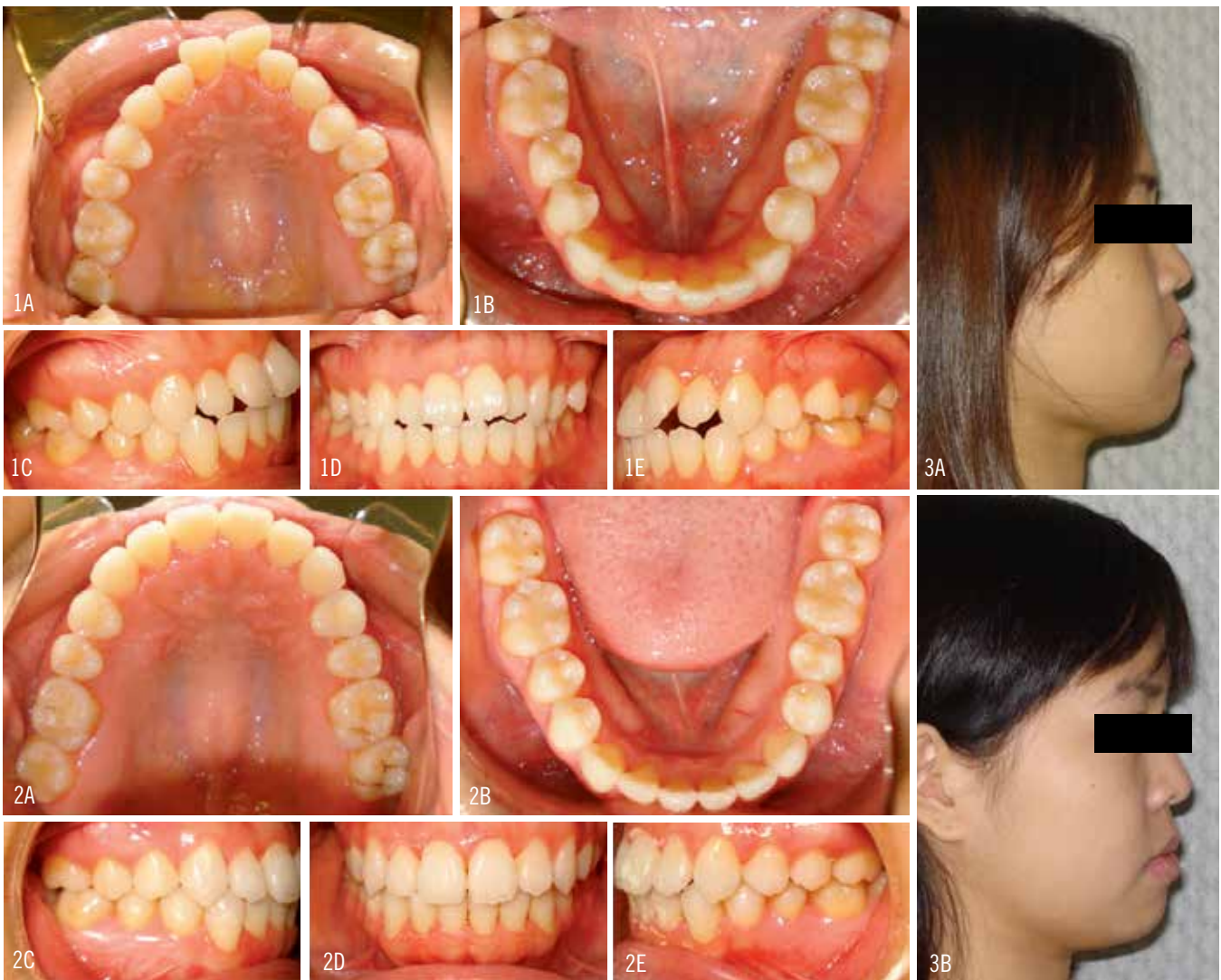wear anterior vertical elastics to translate all the intrusive force to the posterior teeth.

The MEAW appliance is very effective but has two drawbacks. The first is hygiene as the many boot-loops are food and plaque collectors; and second is compliance, in that if a patient does not wear the anterior vertical elastics, the open bite will get much worse. It is fair to say that no open bite has gotten worse when treated with Invisalign, which is often the case with fixed appliances if not planed or executed correctly.

Case 3

Total treatment time of 14 months with no IPR or refinement. Patient presented with facial and mandibular asymmetries, buccal crossbite of number 13, and cant to the smile line with a protrusive lower lip. Better soft tissue profile balance was achieved simply with arch coordination by advancing the upper anterior teeth and retracting the lower anterior teeth. The upper and lower soft tissues responded well to the tooth movement. The smile line was corrected by employing the extrusion protocol on numbers 9, 10, and 11. Please note that the patient still has a slight facial asymmetry, but the incisal edges of the upper anterior now are parallel with the curvature of the lower lip (See figures on page 19).

In the end, to properly manage occlusal cants and reverse smile lines, orthodontists need to understand the strengths and weakness of their aligner appliances: they must maximize its pushing strength and minimize its pulling weakness. To that end, orthodontists must learn to translate the language of fixed appliances to Invisalign aligner therapy. While there are simple imitators, the use of an appliance system that is as sophisticated as Invisalign is causing us to learn a whole new way to talk to teeth in order to tackle more complex



Case 3. Patient presented with facial and mandibular asymmetries, buccal crossbite of number 13, and cant to the smile line with a protrusive lip, as seen in figures 1A-1E and 3A. Figures 2A-2E and 3B show the results of treatment. Treatment time was 14 months with no IPR or refinement.

cases. The challenge is to deconstruct the interactions of the archwire in the bracket slot that we take for granted every day and translate those mechanics into Clincheck design.

Criticism is often directed toward Align for not doing this automatically so that every Clincheck is designed to “work properly and to consistently get ideal results.” In continuing that logic, Align would then be criticized for making it easy for every general practitioner to treat the same complex cases and malocclusion that we can. By such reasoning, Align can’t win either way. Didn’t we hear such howls with the advent of the straight-wire

appliance and direct bonding ability making banding every tooth obsolete? What about today’s customized wires and braces with CAD/CAM technology and indirect bonding making it easier than ever to do orthodontics?

The point is we should not worry about such folly, but rather focus on our own ability to deliver outstanding results employing the basic principles of tooth movement physiology combined with whatever appliances system we decide to use.

While it is true that these cases could have all been treated with braces with or without fancy software and technology to customize wires and brackets with the use of

TADs to augment force systems, at the end of the day such treatment would still use braces. The usual issues of hygiene and patient dissatisfaction of wearing braces is well understood, especially for the ever-growing number of adult patients. Patients’ demand for cosmetically minded therapy is constantly increasing, and being able to accomplish the same results for both adults or teens using removable aligners as with the Invisalign System is what will truly make one’s practice stand out from the rest.

Now that Invisalign, aligner therapy, and in-office scanning technology have without argument established themselves as

legitimate treatment modalities in modern orthodontics, the next paradigm shift in orthodontics will be to augment a patient’s own biology to not only facilitate tooth movement but also enhance the stability of the result. Attempts to this end have been made in the past (Relaxin as a therapeutic adjunct), but such technology already exists in the marketplace (Propel Orthodontics); stay tuned for more advances in the near future. This will be a welcomed adjunct to therapy to help with the eventual withdrawal of fixed appliances in orthodontic practice, reserving them for only a minority of cases and the history chapter in orthodontic textbooks. **OP**